

## REI CASE 3 PART B

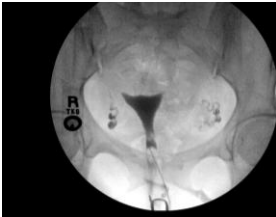Ms. Smith presents to clinic today to discuss results of diagnostic testing.

### Laboratory Results:

Test	Result	Reference Range
Urine $\beta$ -HCG	negative	
TSH (miu/mL)	0.776	0.4000 – 5.000
Prolactin (ng/mL)	20	<25 premenopausal
GC/CT	Negative	
Progesterone (day 21)	7.8 ng/ml	>3-5 ng/ml = luteal phase

### Radiology: HSG

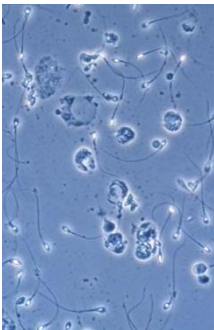
Normal uterine shape, both tubes filled and spilled



Hysterosalpingogram (Image provided by Brenda S. Houmard, MD PhD, University of Washington, Seattle, Washington)

### Semen analysis:

Concentration:	215 million/mL	(> 20 million/mL)
Motility:	70%	(> 50%)
Rapid progressive	18%	(> 25%)
Linear motility		
Normal Morphology	18%	(>13%)
WBC/mL	2 million/ml	(<1 million)



Leukocytospermia (Image provide by Charles H. Muller, PhD, University of Washington, Seattle, Washington)

## Case Questions:

1. Is this a normal evaluation? How would you counsel this couple?
2. What are the treatment options? What are the approximate costs, risks, and success rates of each option?
3. How does the patient's age impact the success rate of the treatment you recommend?