


CHAPTER 10

URINARY DIVERSION AND BLADDER AUGMENTATION PROCEDURES

Section 10.1: Mainz II pouch and ileal conduit

Section 10.2: Bladder augmentation

About 5% of all VVFs fall into the category of deemed incurable fistulas. However, there is no standard definition of what constitutes an incurable fistula and significant experience is necessary to make this decision. *Reference: Urinary diversion in the vesico-vaginal fistula patient: General considerations regarding feasibility, safety, and follow-up: S.D. Arrowsmith IJOG (2007) 99, S65–S68.*

RECOGNISING FISTULAS THAT CANNOT BE CLOSED OR WHERE DIVERSION IS REQUIRED i.e. where reconstructing normal anatomy or function is not possible.	
<i>Bladder destroyed</i>	<ul style="list-style-type: none"> • If there is total bladder destruction, she will need a diversion (see section 10.1). • If there is a small bladder but an intact urethra, you can augment the size of the bladder (see section 10.2).
<i>Urethra destroyed</i>	<p>There are two options:</p> <ul style="list-style-type: none"> ➤ If the bladder is intact but the urethra is absent, you can potentially construct a neourethra. ➤ The lower end of the bladder can be closed off: <ul style="list-style-type: none"> • Occasionally these cases are suitable for a Mitrofanoff procedure where the appendix is used to form a channel between the bladder and the abdominal wall. • A suprapubic catheter may be a simpler option.
<i>Combination</i>	A combination of factors is often present e.g. several failed repairs, a lot of scarring, sub-total bladder destruction, or a destroyed urethra.
	The decision that a fistula cannot be closed should only be made by an experienced fistula surgeon. If possible two experienced surgeons make this decision together.
<i>Summary</i>	<ul style="list-style-type: none"> • Good urethra + small bladder = augment bladder • Bad urethra + good bladder (> 100 ml) = Reconstruct the urethra or Mitrofanoff procedure or suprapubic catheterization • Bad urethra + small bladder = Diversion?

TREATMENT OPTIONS

If you decide that you cannot close the fistula, the options are:

(A) **Non-surgical:** There is a tendency with medical staff to want to do something to help the patient. However, there is no ideal method of diversion and complex procedures entail significant morbidity and mortality.

Doing nothing is not an option, but we should try to provide the patient with:

- Pads and barrier zinc oxide cream which is a safe alternative.
- Free visits at a clinic with free medications.
- Social and financial support.

These will make the life of the incurable patient substantially easier. These patients need lifelong care, with or without diversion.

(B) **Surgical:** There are no really good options.

- *Mainz II pouch:* This may be thought of as the 'least worst' option in low-resource settings because of the straightforward surgical approach and the socially acceptable resultant voiding function.
- *Ileal conduit:* This requires the patient to live near to a supply of stoma bags. So for many patients, this is not an option unless these can be provided.
- *Continent pouch* where the patient catheterizes herself e.g. Mitrofanoff appendico-vesicostomy procedure. However, it can be difficult to close off the lower bladder. This is usually best done by mobilizing first from below (vaginally) and then closing from above (abdominally). There is a risk of leakage vaginally if the lower bladder does not heal.
- *Suprapubic catheter/ diversion:* While not often mentioned, this is sometimes an option if the bladder neck has closed due to scarring. It is also possible to close the lower end of the bladder either suprapubically or

vaginally where it is not possible to have a functioning urethra e.g. in severe cases of stress incontinence that have failed other treatments. The bladder would have to be of adequate size to perform this. It may avoid doing a more formal diversion.

- The opening is normally placed two fingerbreadths (3-4 cm) above the pubic symphysis and if necessary, it can be lateral to the midline if you have just done a midline laparotomy. If done as an open procedure, stay extraperitoneal. If made too low down, it is more difficult and probably less comfortable. The catheter does not have to be stitched in and can be retained by the balloon.
- If the catheter falls out, it needs replacement within a few hours as the track closes off quickly, resulting in urinary retention. Therefore she ought to be able to get to hospital quickly to have it reinserted.
- The patients tend to do better with a catheter of reasonable diameter i.e. 16,18 or 20 F.
- The initial catheter should be changed after 5 weeks. Thereafter, if it is latex it should be changed monthly and if silicone, change three monthly.
- In the long-term, any indwelling catheter can be complicated by urinary infection, bleeding, bladder stones and rarely bladder cancer.
- Some patients leak around the catheter but this is from bladder spasms so oxybutynin may help. If the catheter blocks, they will also leak around the catheter.

Reference: The ethical and technical aspects of urinary diversions in low-resource settings: a commentary BJOG. 2016 Jul; 123(8):1273-7. Wilkinson J et al.

(10.1) MAINZ II POUCH AND ILEAL CONDUIT

MAINZ POUCH II

Before considering a Mainz II pouch, the following criteria should be met:

- (a) The patient should have normal or almost normal renal function. If renal function is impaired, the patient is more likely to become acidotic. Renal ultrasound should also be performed. If there is moderate or severe bilateral hydronephrosis, then a pouch is contraindicated.
- (b) HIV test: the procedure is best avoided if HIV positive with low CD4 counts or high viral loads.
- (c) The patient should have an intact anal sphincter. This can be tested by getting her to hold an enema of 250 ml for 60 minutes while walking around. A useful tip is to add dye to the enema so that you can distinguish anal leaking from the urine leak from the VVF. Wipe carefully after injecting the dye. She should wear a pad which should be unstained by dye after 60 minutes.
If she has a sphincter tear: This would have to be repaired first. Provided she can hold 250 ml of dye without leaking, she should then be suitable for a Mainz pouch. However, others would consider an anal sphincter injury to be a relative/absolute contraindication for diversion. We know that even after repair, sphincter function will be compromised and deteriorate in the majority of patients. That may lead to nightly soiling of the bed as the internal anal sphincter relaxes.
- (d) Make sure she does not have an RVF. There may be an unrecognized RVF in a tight band of scar as patients with bad VVFs often have an (unrecognized) RVF. Repeat a dye test immediately before surgery in the operating room.
- (e) Informed consent must be obtained. She should understand that:
 - Both urine and stool mixed will now pass via the anus.
 - Night soiling with incontinence of liquid stool may occur, probably worsening with age.
 - By obtaining continence, this could shorten her life-span due to long term complications such as acidosis, renal failure and colonic malignancy.

It often helps the patient to meet another patient who has had the procedure. It is not uncommon to find patients who want their Mainz pouch reversed after 5-10 years and who would not have chosen the procedure if they had fully understood what it involved. Many patients will prefer to stay incontinent rather than passing/ leaking urine with stool.

- (f) Ideally, she should live relatively near the centre as long-term follow up is essential.



If the patient has had a VVF or an RVF repaired, always check that there is no leak from the rectum regardless of what the patient says. Even a small leak will reveal itself once urine is in the colon.

In one study, the overall peri-operative mortality was 2.5 %. *Reference: Urinary diversion for patients with inoperable obstetric vesicovaginal fistula: the Jos, Nigeria experience: Kirschner C.V. Lengmang S.J. Karshima, J.A., Arrowsmith, S. Int Urogynecol J June 2016; 27(6):865-70.*

However, the five-year mortality may be a lot higher so it is not a procedure to undertake without careful discussion with the patient. She must be intelligent enough to understand all the possible problems.

The main advantage of this operation over simple ureteric implantation into the colon is that the patient is less likely to leak when asleep although it still happens. It creates a high volume but low-pressure pouch.

PRE-OPERATIVE

- Full bowel preparation may be undertaken, or alternatively the lower bowel should be washed out.
- Put in a wide rectal tube for drainage of urine (e.g. a size 7 or 8 endotracheal tube). If this is difficult to insert because of a rectal stricture, it can be passed from above during the operation i.e. pass a clamp from below and pull the tube down, or pass clamp from above and pull tube up.
- If there is still stool in the rectum, using a bladder tipped syringe, irrigate through the rectal tube with betadine/ saline solution until it runs free of debris.

OPERATION

There are two variations to the Mainz II pouch. The following description is that of a single loop pouch. The double loop pouch is described later.

- Make a midline abdominal incision. While holding the loop of sigmoid, put a pack up on each side to push the small bowel into the upper abdomen.
- On the left side, cut the peritoneum lateral to the sigmoid colon which will help mobilize the sigmoid and will also help find the ureter on the left.
- Divide the ureters before making the pouch as this would be difficult to do later. The exact level is not critical so anywhere convenient in the true pelvis is acceptable. When you hold the ureter up with Babcock's, cut underneath to free it. If there is bleeding as you dissect the ureter off, do not be afraid to use cautery cautiously.
- The pouch should measure 10 cm in length of sigmoid on each side and is formed by joining the two sides of the sigmoid together by a side-to-side anastomosis (Fig. 10.1).
- All the surgery is done from the anterior aspect (i.e. in front of the bowel).

(Step 1) Posterior outer layer: Suture the two intact sides together (see Fig. 10.1) continuously, starting superiorly and continue for approximately 12 cm. The important point is to make sure the sutures are in the bowel wall and to avoid the mesentery of the bowel. Try to bite into the muscle along the taenia coli. When correctly done, you should not see fat between sutures. This layer of sutures will become the posterior outer layer.

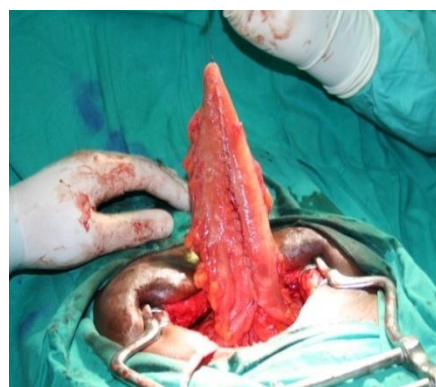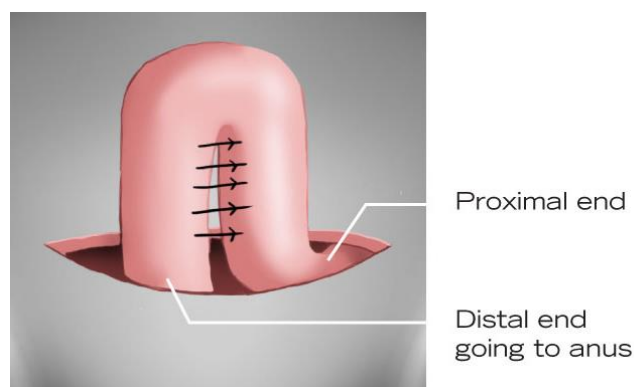


Fig. 10.1a and b: Show the initial joining of the two loops of sigmoid with the posterior outer layer stitched.

(Step 2) Incision: (see Fig. 10.2) Start at the top and work your way down on each side. If you cut along the taenia coli you get less bleeding and the edges will hold the sutures better. This incision is made 3 to 5 mm from the initial suture line. It is safer to open the bowel with scissors rather than cautery.

(Step 3) Stitch posterior inner layer: (Fig.10.3) Make sure you are getting full thickness of mucosa and muscle. With a continuous stitch, start proximally and when you reach the distal end, come out of the bowel

lumen with the stitch. Take one bite on the outside and lock (\pm tie) the stitch so that the tension is maintained on the suture. You can leave the suture attached to the needle holder and use it later for the anterior layer.

(Step 4) Ureters inserted into bowel: A site for ureteric insertion should be selected about half way along the posterior wall. If you place the opening too high up, there will be a gap under the ureters where bowel could potentially become trapped.

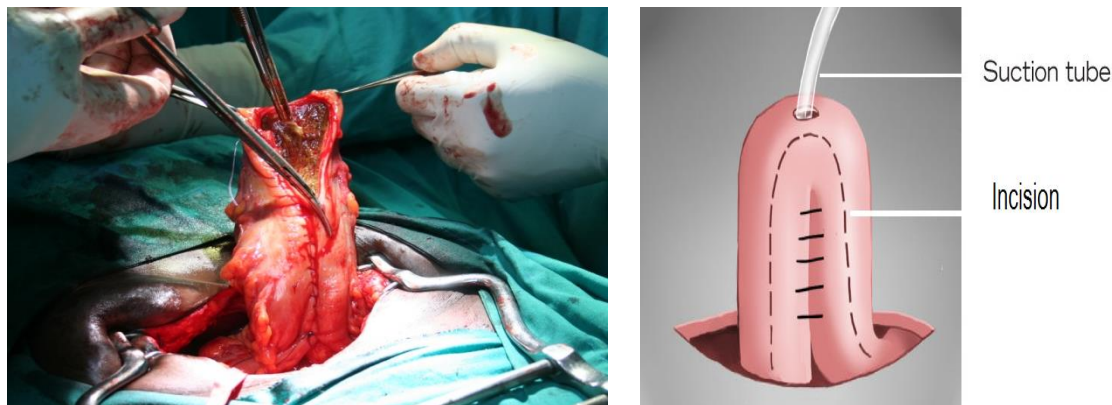
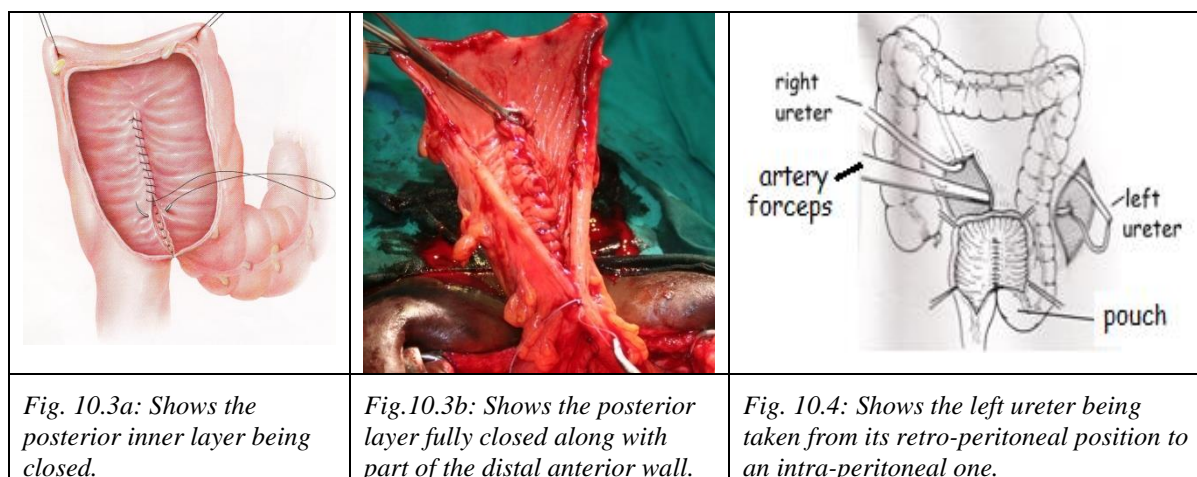


Fig. 10.2: a + b: Open the apex of the loop and incise the bowel on either side of the first layer of sutures.



- The right ureter is usually easy to insert as it sits beside the pouch. The left ureter is more difficult. Using a long artery forceps (Fig.10.4), bring the left ureter from its retroperitoneal site on the left (going through the mesentery of the sigmoid colon or behind the descending colon) to lie close to the right ureter. Make sure to pick a puncture site free of mesenteric vessels. If necessary, make a small opening in the peritoneum over the mesentery of the sigmoid with cautery so that you can see an avascular area.
 - Put a 3/0 stitch onto the end of the ureter to avoid pulling on the ureter directly with a forceps (see Fig. 9.1d).
 - Pull the ureter into the colon by making a stab incision with an artery forceps.
- Once the ureters are pulled into the colon, place a ureteric catheter in each. (If the ureter is not enlarged, spatulate the ends (see Fig. 9.4). Either:
- Attach the mucosa of the ureter to the bowel mucosa with several interrupted sutures (see Fig.10.5).
 - Pull in 2-3 cm of the ureter to make a spout and stitch the bowel mucosa to the side wall of the ureter. If you do this, you can then make a second layer by stitching the ureteric mucosa to the bowel mucosa. See chapter 9 for the technique of ureteric re-implantation.

- Fix the ureteric catheters to the pouch mucosa with plain catgut to prevent them being expelled by peristalsis. Also, fix them on the outside of the bowel wall.
- Pass the ureteric catheters into the rectal tube and suture them to the tube so that when the rectal tube is removed, the ureteric catheters will be removed at the same time.

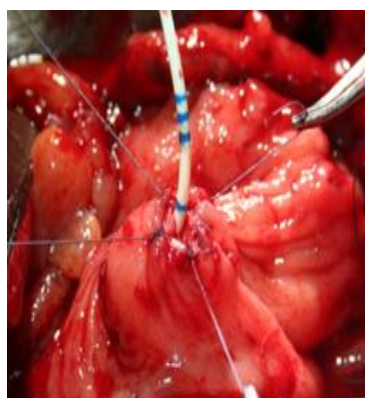


Fig. 10.5: The ureter has been sutured to the colonic mucosa.

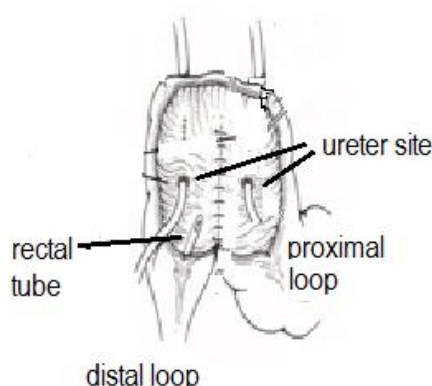
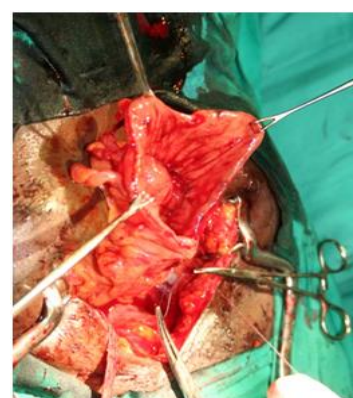

Fig. 10.6 a and b: The ureters are implanted, the anterior layer is about to be closed.



(Step 5) Anterior layer

- *Inner layer:* This is done continuously initially with the suture previously used for the inner layer of the posterior wall. However, it is usually necessary to also use another suture which is best started at the apex/proximal end and joins the initial suture in the middle of the pouch.
- **⚠ Tip!** To get the mucosa to invert and to get good bites of the bowel, as you insert the needle just above the mucosa, push the mucosa down with the needle.
- *Outer layer:* It is better not to do a continuous second layer anteriorly because it can create too much tension and stitch holes, which are then very difficult to deal with. It is better to place interrupted sutures only if you see there are any gaps in the anterior inner layer.

Abdominal drains may be placed on each side near the site of the ureteric mobilization. These are best made with the tubing (drain) and urine bag (to collect any fluid) that attaches to a Foley catheter.

POST-OPERATIVE CARE

- Leave the rectal tube (with the ureteric catheters attached) in for 7-10 days. If you do not secure it well (e.g. with nylon) to the anal region, it will fall out early.
- Start sips on day 1, then fluids or a light/ soft diet for four days.

If the pouch breaks down

The following is how I have managed this difficult situation:

- (1) Do a transverse de-functioning colostomy.
- (2) Through the area of breakdown, re-insert ureteric catheters into the ureters and pass a rectal tube up from the anus if the original one has come out.
- (3) Close the area of breakdown with interrupted sutures.
- (4) Place a drain in the pelvis in case there is any urinary leak.
- (5) The colostomy can usually be reversed after 3-6 months.

If there is a leak from the ureter: this is more likely to occur if the ureteric stent falls out. This will require re-operation and re-implantation of the ureter.

LONG TERM RESULTS AND PROBLEMS OF THE MAINZ POUCH

The Mainz pouch has an important place in all parts of the world but is particularly useful in settings where stoma bags are difficult to obtain.

- (1) *Acidosis:* develops in about 50% of patients by four years due to colonic re-absorption of acid from the urine. It may present with weight loss. Normal renal function can often compensate for the acidosis. To

prevent acidosis, give sodium bicarbonate (baking powder) 600 mg twice daily or 2.5 ml (half teaspoon) each day dissolved in a glass of water and advise regular voiding. Patients should probably not go all night (i.e. seven hours) with a loop of colon full of urine.

- (2) In a patient with compromised renal function, a Mainz pouch will make it worse due to resorption. In patients with normal renal function, the urea only rises slightly.
- (3) *Tumours*: 20% develop tumours in the sigmoid colon by 20 years. The earliest report of a tumour is at 12 years.
- (4) *Uro-sepsis* risk is increased. If they have repeated infections, you need to consider uretero-colic stenosis. Overall the best policy is that the patient needs to go to hospital if they get unwell no matter what the diagnosis is
- (5) *Obstructive nephropathy*: May present with recurrent pain and pyelonephritis. It may occur for two reasons:
 - Uretero-colic stenosis: Tunnelling the ureters under the mucosa for three cm was previously recommended to reduce reflux and fix the ureters more securely. However, this has been found to increase the risk of later stenosis at the site of implantation and about a third of all patients develop hydronephrosis and renal impairment if tunnelling is performed. A simple end to side anastomosis is adequate. The disadvantage of anything more complex in achieving an anti-reflux tunnel is that there is always a risk that the blood supply to the end of the ureter will be compromised by more complicated surgery, leading to a stricture.
 - Functional obstructive nephropathy is due to a gradual rise in pouch pressure towards normal colonic pressure, which is much higher than bladder pressure (upper limit at rest about 15 cm H₂O). Eventually, the upper tract pressure will have to rise above 15 cm to push the urine out i.e. there will be a state of obstruction and, even without a stricture, hydronephrosis and eventually obstructive nephropathy will develop. (The kidneys can only tolerate pressures up to 20 cm H₂O). This course of events is not prevented by including the anti-reflux procedure with the anastomosis.
- (6) *Wet at night*: the incidence seems to be higher in fistula patients compared to others. One study reported that 30 to 50 % of fistula patients are wet at night following the Mainz Procedure (Mike Bishop unpublished data). To reduce the risk of nocturnal incontinence:
 - Advise the patient to reduce her fluid intake in the evening.
 - Have the patient wake up to void during the night with an alarm.
 - If new onset leakage of urine develops during the night or even during the day, tightening up their sphincter may help at least for a few years.
 - Another option is to use the Double Loop Pouch. In a series in Addis Ababa Fistula Hospital, nine out of ten patients were dry at night.

DOUBLE LOOP MAINZ POUCH

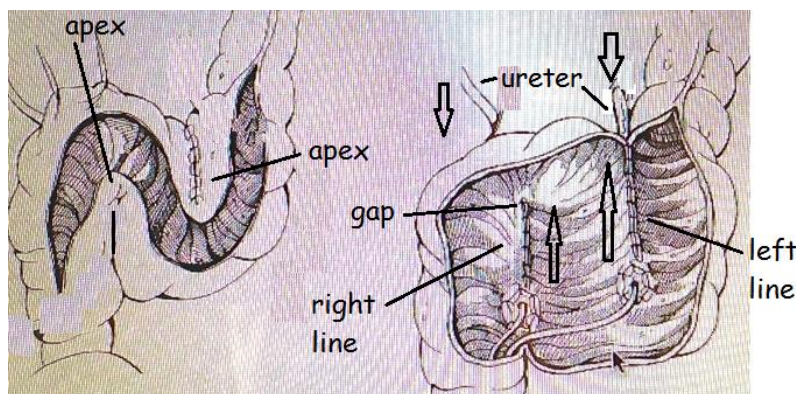


Fig. 10.6c: Shows the incision made for the double pouch. Fig. 10.6d: Shows the two posterior walls closed and the ureters brought into the pouch. The lower arrows indicate the direction of closure of the posterior outer layer on each side. The upper arrows show the direction the two ureters are pulled in.

This incorporates the lower part of the descending colon into the pouch to make a larger pouch. According to the Addis Ababa Fistula hospital where this larger pouch is performed, there are several advantages:

1. As the pouch is larger, the patient is less likely to leak urine, especially during sleep.
2. It is easier to make a tunnel for dilated ureters using an extra-mural tunnel.
3. The risk of stricture and infection is reported to be less.

The disadvantages may be related to the larger volume of urine stored in the pouch which may lead to more resorption of urine and increased risk of acidosis. To avoid this, the patient should void at least once during the night, using an alarm clock to wake her. It is also technically a more difficult procedure to do.

Method:

- It may first be necessary to mobilize the descending colon as far as the splenic flexure.
- The incision is made as shown in Fig. 10.6c.
- Closure is performed as in Fig. 10.6d with the left posterior wall first, then the right posterior wall and finally the anterior wall.
- All the suture lines are done continuously.

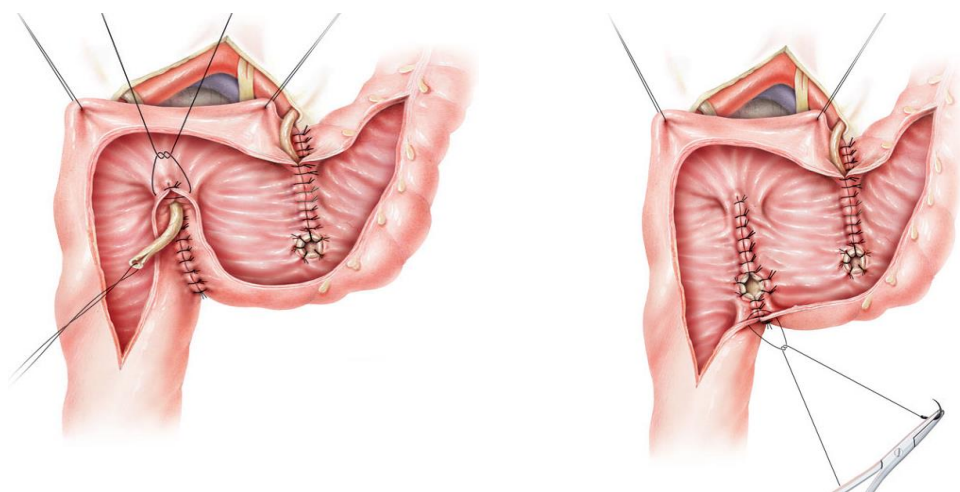


Fig. 10.6e: Shows the left ureter already fixed in the pouch and the right brought in but not yet fixed.

Fig. 10.6f: Shows the same as Fig. 10.6d.

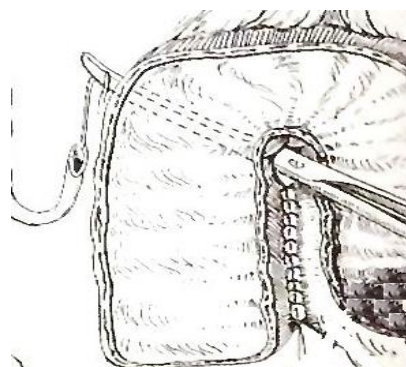


Fig. 10.6g: Shows the right ureter being brought into the pouch.

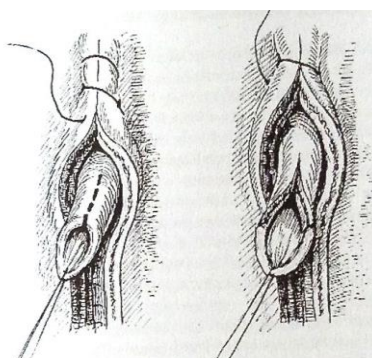


Fig. 10.6h: When cutting ureter, always cut obliquely and spatulate. Once the ureter is brought into the pouch, it is fixed into position by suturing the mucosa over it so that only the meatus is not covered.

- *Posterior wall: left side closure:*

1. Starting at the left apex and working proximally, make a posterior layer which is below the mucosa. Go from distal to proximal. This will create the base of the tunnel for the ureter which is placed on top of this layer. Some prefer to use 3/0 or 4/0 Prolene rather than Vicryl for this layer.
2. The left ureter which has been brought in intra-peritoneally is now pulled in to lie on top of this layer. Pull the ureter distally to make it straight as you fix it.
3. Close the mucosa over the ureter (Fig. 10.6f). As the ureter often ends up about half-way along the suture line (left line) you may have to close the proximal mucosa first and then the distal part.
4. Check that the ureteric catheter runs freely in the tunnel.

- *Posterior wall: right side closure:* The same steps are repeated on the right side but you have to leave a gap (see Fig.10.6d+g) to allow the ureter to be pulled in. Use a slightly curved instrument to pull it in rather than one that is too angled.
- *Anterior wall:* Close the anterior layer in one layer. Start at the right lower corner and finish at the left upper corner. You may end up with two ‘corners’ on the right side so you may have to do these separately.

ILEAL CONDUIT (see Appendix 6 for check-list for counselling the patient about this procedure).

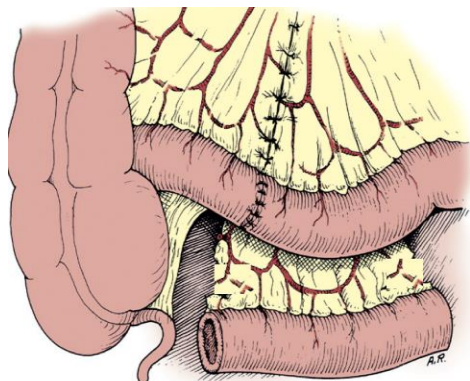


Fig. 10.6i: Shows the ileal conduit formed.

(a) *Prepare the conduit:*

- A 15-20 cm segment of lower ileum is used with the length long enough to reach the abdominal wall. Avoid the terminal 15-20 cm of the ileum (needed for absorption). Mark the distal end with a long stitch and the proximal end with a short stitch.
- The incision in the mesentery needs only to be 5-7 cm to give the segment enough mobility. Transilluminate the mesentery to see the blood supply before cutting.
- The main bowel is re-anastomosed above and medially so that the ileal conduit is below and lateral.
- Flush the segment of ileum with saline.

- (b) *Prepare the ureters:* The left ureter must be brought to the right side over the great vessels and posterior to the sigmoid mesentery as in Fig. 10.4. Spatulate the ureters for 0.5 cm.
- (c) *Insert the ureters into the conduit:* The ureters are inserted separately to the side of the ileum using the method described in Fig. 9.2 c +d. Place the left ureter at the left end and the right ureter somewhere along the loop. Make a small incision in the bowel wall using an artery forceps inserted into either end of the conduit to tent up the bowel as you cut. Suture the full thickness of the ureter to the full thickness of the bowel with interrupted sutures. Take good bites on the bowel as you cannot narrow it.
- (d) The anastomosis is stented with a ureteric catheter. Pass the Yankauer suction tip or a long artery forceps down the loop and feed the ureteric catheter into it to bring it out the end of the ileum.
- (e) *Close the proximal end of the conduit.*
- (f) *Bring the conduit through the abdominal wall.* To make the stoma, pull on the skin with an Allis forceps and cut an oval hole. You can also hold the fascia with an Allis forceps before making a cruciate incision. It is important that two fingers can pass through the tunnel.
- (g) *Make a spout:* You need to make a spout of at least three cm. To get the bowel to evert, pass a Babcock’s forceps into the lumen and grasp the mucosa at least 3 cm down. Then holding this, pull the bowel mucosa up. To keep the bowel everted, stitch from the skin edge to the outer bowel serosa about 6 cm down and then to the edge of bowel mucosa. Insert four of these sutures. Then the rest of the defect is closed by suturing the bowel mucosa directly to the skin. You do not want any gaps between sutures large enough that you can put your finger into.

(10.2) BLADDER AUGMENTATION

INDICATIONS

- *Post VVF repair:* This is occasionally indicated in a wet patient (VVF closed) where the bladder is very small but there is a functioning urethra. In cases where the urethra may be incompetent, a deliberately obstructive sling may be inserted either before the augmentation or at the same time. As the patient will have to do self-catheterization anyway, if retention occurs this will not be a major problem.
- *During VVF repair:* It is very occasionally performed at the same time as a VVF repair when there is a very small bladder ± a ureter which needs to be re-implanted. The only time I have done this was for a high VVF where there was a good urethra. The bladder was only able to hold the Foley balloon with 3-4 ml inflated. The right ureter needed to be re-implanted. By enlarging the bladder, this made it easy to re-implant the ureter into the new (bowel) part of the bladder.

Ideally, the patient should be able to perform intermittent self-catheterization before the operation as she will need to do it after the operation.

OPERATION

(a) *Bladder*: First mobilize the bladder all around. Start by placing dissecting scissors in the midline just behind the pubic bone and spread them. Then work laterally on each side to free the bladder from the pubic bone, using cautery if necessary. The bladder is then opened longitudinally (some prefer transversely) in the midline, dividing both the anterior and posterior walls (Fig. 10.8A).

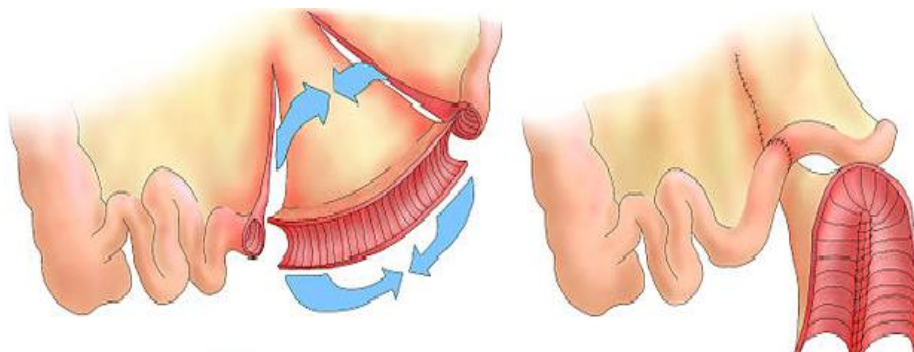


Fig. 10.6j: Shows the segment of bowel taken from ileum and the ileum is re-anastomosed. The segment for the augmentation is brought below the re-anastomosed bowel.

(b) *Bowel*: A 20 cm segment of the lower ileum (Fig. 10.6j) is used to increase the bladder size. The blood supply is kept intact through the mesentery. Avoid the terminal 20 cm of ileum, as this is essential for absorption of Vitamin B12. The bowel is re-anastomosed before proceeding with the next step.



When operating on the intestine, avoid using cautery within 2 cm of where any anastomosis will be made. Therefore it is much safer to cut the intestine with scissors.

(c) *The augment*: After isolating the bowel, open along the anti-mesenteric border with scissors (Fig. 10.7B). First, the opened loop is stitched to itself longitudinally (Fig. 10.6j and 10.7C). This suture should be continued around the corner so that points 1 and 4 end up together as in Fig. 10.7C. It can be further stitched to itself on each side (Fig. 10.7D) to make it a more dome shape (Fig. 10.8B) which reduces the length of the edges. This makes it easier to suture to a small bladder.

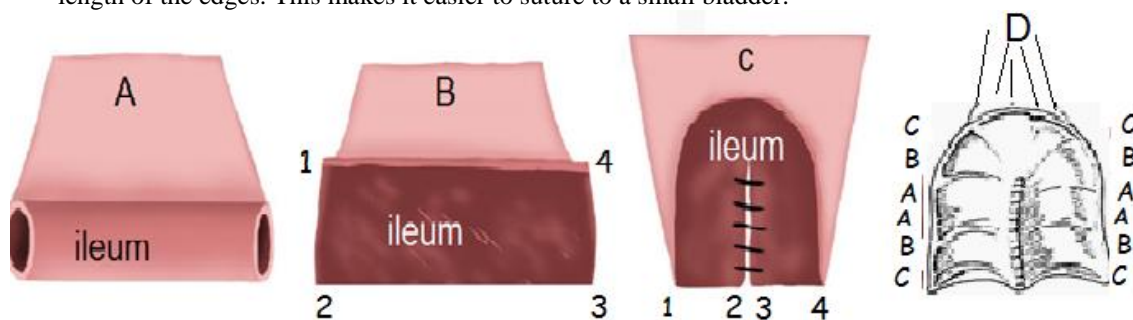


Fig. 10.7: A shows the isolated loop of ileum; B: shows the ileum opened along the anti-mesenteric border and C then folded onto itself by suturing the inner edges. It is then D sutured on each side by taking bites from A to A, B to B and C to C on each side which results in a more dome-shaped piece of bowel.

(d) *Attaching the bowel to the bladder*:

- First, the posterior part of the bowel dome is stitched to the posterior wall of the bladder.
- This is done by using two separate sutures starting in the midline posteriorly. Go from out-to-in on the bladder and in-to-out on the bowel. Place and tie both sutures. Make sure there is no gap between these sutures.
- Continue one continuous (full-thickness) suture around to the left side and the other to the right side (Fig. 10.8B).
- When the posterior and lateral walls are sutured, the anterior part of the bowel dome is then stitched to the anterior bladder wall. This is easier to do than the posterior. You may start again in the midline anteriorly with two separate sutures and work laterally, or you may work from lateral to the midline anteriorly.

! Tip! If you end up with excess bowel to close to the bladder anteriorly, then stitch the bowel to itself longitudinally.

- Place a suprapubic catheter (preferably 24 F) for 21 days and a urethral catheter (18-20 F) for 28 days. The reason for leaving the urethral catheter longer is to prevent leaking from the bowel segment at the suprapubic catheter site once the catheter is removed. It is difficult to place the suprapubic catheter through the native bladder since it is often so low down and lateral after the augment.
- An abdominal drain must be placed near the bladder which is left in for at least 7 days. The drain should only be removed if the drainage is < 100 ml/ day.

! Top Tip! It is a good idea to transfix the abdominal drain so that it does not come out prematurely.

- Some surgeons irrigate the bladder daily via the suprapubic catheter to clear mucus. It then should flow out of the urethral catheter.
- Mucus can give the urine an “infected appearance”. However, only treat for urinary tract infection if the patient has fever and renal angle pain.

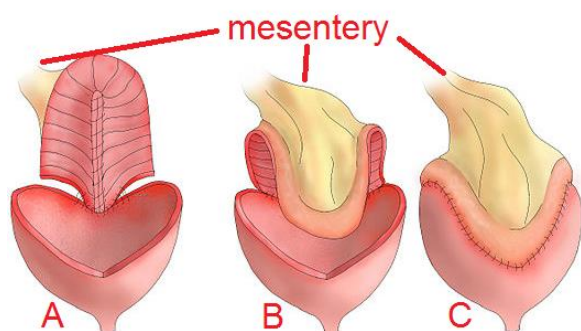


Fig. 10.8: A shows the bladder split open longitudinally and the posterior part of the bowel is being sutured onto the posterior bladder. In B the posterior wall is almost complete and then in C the anterior wall is now sutured.

POST-OPERATIVE PROBLEMS

There are two common and two less common problems with an augmented bladder:

- (a) Mucus can be a problem for many months (especially in the first 3-6 months) and there is the risk of mucus causing urinary retention and rupture of the augmented bladder. To avoid this, the patient needs to catheterize herself once a day. The larger the catheter, the better evacuation of mucus will be.
- (b) It is likely the patient will not empty her bladder well due to the size of the augment. The bowel section will over distend and stretch out. The bladder can quickly develop 1,000 ml capacity and may never void well again. Using less bowel during the augment does not reduce this risk because of the small contracted native bladder. To avoid this, the patient should catheterize herself at least 2 to 3 times a day.

If the patient is voiding well or can empty with straining (Valsalva) or suprapubic pressure, then self-catheterization once a day may be all that is required (to drain excess mucus). However, to empty the bladder of urine completely 2 - 3 times a day will be the norm. How often it is done partly depends on what level of residual you are prepared to accept.

- (c) Bladder stones occur occasionally in augmented bladders secondary to mucus balls or presence of suture material. Haematuria or recurrent infections should alert the clinician to investigate for this. Stones as large as 18 cm have been reported in augmented bladders. If the bladder is kept empty, stones should be rare.
- (d) There is a very small risk in the long-term of cancer at the bowel/ urothelial junction.