

*This chapter should be cited as follows:*


Oikonomou M, Chandraharan E, *Glob. libr. women's med.*,

ISSN: 1756-2228; DOI 10.3843/GLOWM.415143

## **The Continuous Textbook of Women's Medicine Series – Obstetrics Module Volume 11**

### **LABOR AND DELIVERY**

**Volume Editor:** *Dr Edwin Chandraharan, Director Global Academy of Medical Education and Training,*



## *Chapter*

# Management of Second Stage of Labor

First published: February 2021

## **AUTHORS**

**Maria Oikonomou, MD, MSc, PhDc**

*Clinical Fellow in Obstetrics and Gynecology, Watford General Hospital, Watford, UK*

**Edwin Chandraharan, MBBS, MS (Obs & Gyn), DFRH, DCRM, FSLCOG, FRCOG**

*Director Global Academy of Medical Education & Training, London. Formerly, Lead Consultant Labour Ward, St George's University Hospitals NHS Foundation Trust, London & Honorary Senior Lecturer, St George's University of London, UK*

## **INTRODUCTION**

The second stage of labor refers to the period that elapses between the onset of full dilatation of the cervix, and delivery of the fetus. It is further divided into a "passive" phase which involves a progressive descent and rotation of the presenting part, and an "active" phase of maternal expulsive efforts.

The second stage of labor is very important because it is associated with increased maternal and perinatal morbidity and mortality as a result of the rapidity of onset of hypoxic stress to the fetus, as well as perineal trauma to the mother owing to the mechanical forces operating during the final stages of labor as the hard and bony fetal head traverse the maternal soft tissues that comprise the birth canal.

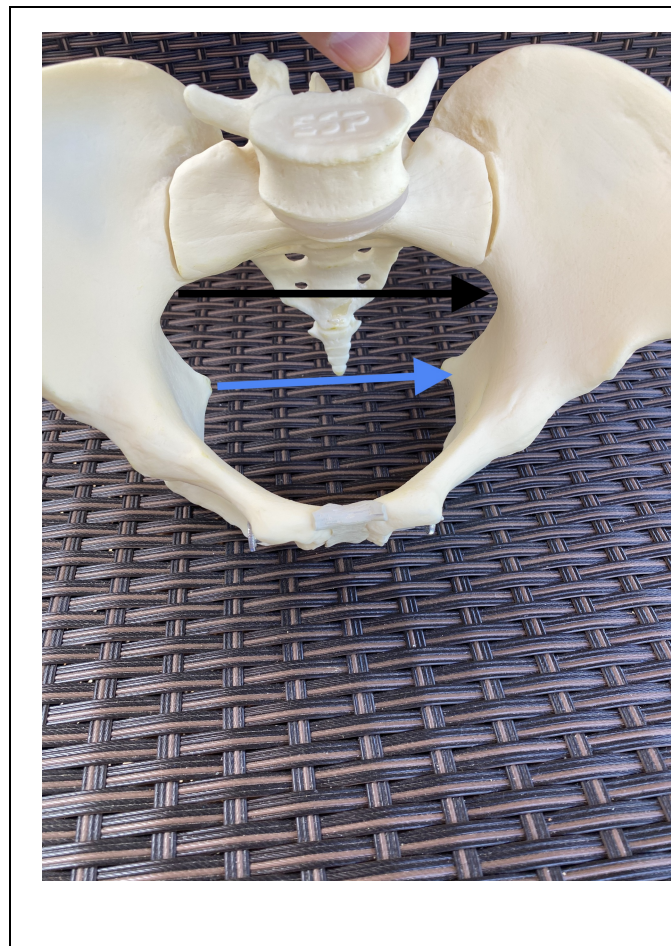
This chapter addresses the anatomy of the female pelvis, mechanism of labor, fetal monitoring specific to the second stage of labor, the conduct of operative vaginal births and measures to avoid complications.

## **MATERNAL BIRTH PASSAGE**

The maternal birth passage consists of a bony pelvis comprising of the ilium, the ischium and the pubis, articulating with the sacrum and the coccyx posteriorly, as well as the soft tissues. The latter is composed of ligaments, muscles of the pelvic floor and of the pelvic sidewall, and the muscles of the perineum covered by the skin and subcutaneous tissue. It is important to appreciate that the pelvis is richly supplied by a network of blood vessels with significant anastomoses, as well as nerve fibers and nerve plexuses.

Unlike other "four-legged" mammals, the human pelvis has undergone significant evolutionary changes in view of the erect posture. The female bony birth canal is no longer cylindrical, but, has a narrower anteroposterior diameter at the level of the pelvic inlet due to the projection of the sacral promontory to aid weight-bearing. In contrast, due to the projection of the large ischial tuberosities, as a result of the need to provide attachments to the powerful muscles of thigh which were essential for running and hunting, the pelvic outlet has developed a smaller transverse diameter

(Figure 1).



**Figure 1** Note the larger transverse diameter at the inlet (black arrow) as compared to the outlet (blue arrow).

## THE JOURNEY: “MECHANISMS OF LABOR”

The evolutionary changes in the diameters of the human pelvis necessitated by the assumption of the erect posture by our human ancestors, have had a direct impact on the fetus during second stage of labor. After having entered the maternal bony pelvis in either an oblique or transverse diameter, in view of the narrow anteroposterior diameter at the pelvic inlet as a result of the projecting sacral promontory, the human fetus has to undergo an “internal rotation” in the larger “mid cavity” of the maternal pelvis. This is to ensure that the fetal skull position changes from the transverse or oblique diameter to an anteroposterior diameter, to overcome the restricted space due to the large, laterally placed, ischial tuberosities at the pelvic outlet (Figure 1). In addition, the fetus also needs to traverse the “J” shaped maternal birth passage, called the “curve of Carus”.

The “mechanisms of labor” adopted by the human fetus during second stage of labor (Table 1) is determined by the effectiveness of the uterine contractions (“Power”), the size, position and presentation of the fetus (“Passenger”), and the resistance offered by the bony and soft tissue parts of the maternal birth passage (“Passage”).

The aim of optimizing the management of second stage of labor is to understand and correct the relationship between the Power, Passenger and Passage, so that maternal and perinatal morbidity and mortality can be avoided. It is important to appreciate that an emergency cesarean section during second stage of labor is associated with a significantly increased maternal and perinatal morbidity and mortality. Therefore, every attempt should be made to achieve a vaginal birth, whenever possible, provided it is safe to do so, after performing a thorough maternal and fetal assessment, and considering the overall clinical picture. Women should be appropriately supported throughout the second stage of labor, and should be provided sufficient, evidence-based information to make informed decisions about their care.

**Table 1** Mechanisms of human labor during the second stage.

Mechanism	Definition
Engagement	The widest diameter of the presenting part (i.e. the biparietal diameter in vertex presentation and bitrochanteric diameter in a breech presentation) crosses the maternal pelvic brim
Descent	Downward movement of the leading bony edge of the presenting part inside the maternal birth passage
Flexion	Maximum movement of the fetal chin towards the fetal chest wall when the sinciput presses against the firm pelvic floor muscles due to ongoing uterine contractions, leading to the flexion of the fetal neck
Internal rotation	Rotation of the fetal occiput (in a cephalic presentation) due to the wriggling contractions of the levator ani muscles (i.e. muscles of the pelvic floor) from a transverse or oblique diameter to an anteroposterior diameter
Extension	Upward movement of the sinciput as the fetal head emerges from the resistance offered by the symphysis pubis
Restitution	"Restoration of anatomy" as the fetus attempts to correct the 'twisting' of the neck during internal rotation
External rotation	Rotation of the occiput outside the mother's birth passage, as the fetal shoulders undergo internal rotation
Delivery of the shoulders and trunk	Once the delivery of the fetal head has occurred, and following the internal rotation of the shoulders, the second stage of labor is completed when the fetal shoulders, trunk, buttocks and legs are delivered

## INEFFECTIVE POWER

Uterine contractions have three properties: frequency, duration and strength, and optimum uterine contractions are essential to ensure descent, flexion, rotation of the presenting part and, ultimately, the delivery of the fetus. It is also very important to appreciate that sufficient time should be allowed in between the uterine contractions during the second stage of labor to enable the fetus to obtain fresh oxygen from the placenta and to excrete the carbon dioxide and metabolic by-products into the maternal circulation.

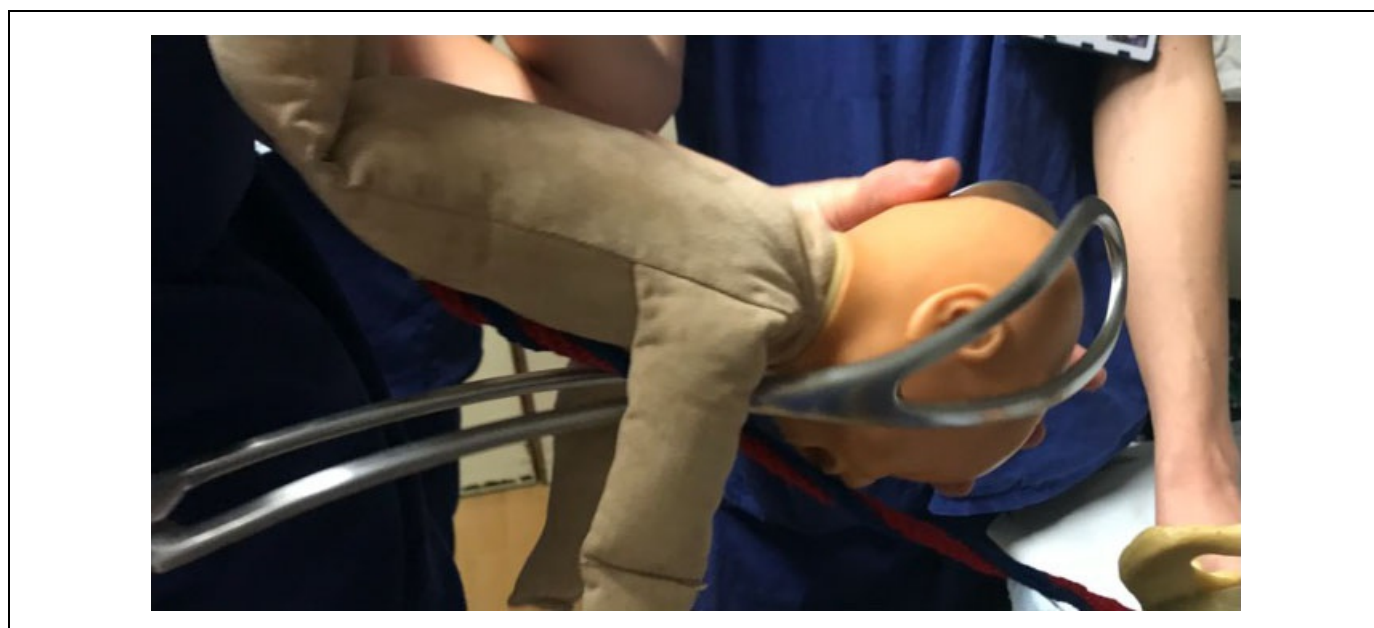In the presence of perceived ineffective uterine activity, it is important to exclude mechanical causes of poor progress of labor during the second stage. These include bony and soft tissue abnormalities of the maternal pelvis (for example, previous road traffic accidents with pelvic fractures, scarring within the birth passage due to previous soft tissue injuries) as well as a relative cephalopelvic disproportion (CPD). Oxytocin should not be commenced during the second stage of labor in the presence of relative or absolute cephalopelvic disproportion. Injudicious use of oxytocin has been shown to be associated with hypoxic ischemic injury thus leading to medicolegal consequences. In a multiparous woman, or in a woman with a previous uterine scar, injudicious use of oxytocin during second stage of labor may significantly increase the risk of uterine rupture. The uterine myometrium is maximally sensitive to oxytocin with increased oxytocin receptors during the second stage of labor.<sup>1,2,3</sup> Therefore, oxytocin should only be commenced after excluding maternal bony abnormalities and a relative cephalopelvic disproportion, beginning at the lowest dose. The second stage of labor should be carefully monitored after commencing oxytocin to determine the progress of labor as well as fetal well-being in order to avoid serious maternal and fetal complications. If there is any evidence of uterine hyperstimulation or abnormal features on the cardiotocograph (CTG) trace, oxytocin infusion should be immediately stopped.

## THE PASSENGER

The main problems involving the passenger during second stage of labor include a relative cephalopelvic disproportion (CPD), abnormal position or deflexion of the presenting part which increases the diameters of the fetal skull and abnormalities in the fetal heart rate. One should not forget that an undiagnosed malpresentation (i.e. a breech or brow presentation) may be associated with poor progress during second stage of labor.

If a relative or an absolute CPD has been excluded, then ineffective uterine contractions can be corrected by the judicious use of oxytocin infusion, with careful maternal and fetal monitoring, to correct deflexion and to facilitate the rotation of the fetal occiput so as to correct the malposition. However, if the ongoing uterine contractions are deemed effective, then, an operative vaginal birth (a vacuum or forceps delivery) should be conducted to correct the deflexion and the malrotation to accomplish vaginal birth.

Specially designed forceps such as the Piper's forceps (Figure 2) may be used to accomplish the delivery of the 'after coming head' during assisted vaginal breech birth. An internal podalic version (IPV) can be performed by an experienced and competent operator to correct the transverse lie of the second twin after the vaginal birth of the first twin.



**Figure 2** Note the specially designed Piper's forceps with long and curved shanks to facilitate application to the 'after-coming' head of the breech.

---

## THE PASSAGE

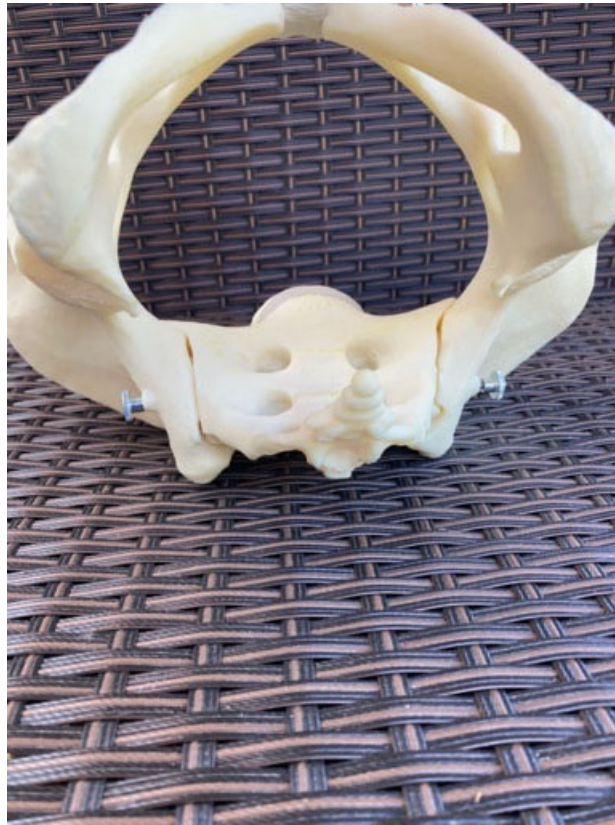---

Bony abnormalities of the pelvic inlet would normally result in non-engagement of the fetal head, usually accompanied by significant caput and molding during labor. Such abnormalities should be recognised during first stage of labor leading to an emergency cesarean section due to lack of progress as a result of the failure of the presenting part to descend and to cause cervical dilatation. Bony abnormalities in the mid-cavity (i.e. prominent ischial spines) are very rare, and, if present, would result in failure of internal rotation leading to fetal malpositions.

If there is evidence of a bony abnormality in the pelvic outlet, such as a narrow subpubic arch (Figure 3), then, an operative vaginal birth should be avoided to prevent serious maternal perineal trauma and fetal injuries. Careful and thorough clinical pelvimetry should be carried out to exclude bony abnormalities in the pelvic inlet, mid-cavity and the pelvic outlet prior to attempting any operative vaginal birth.

Soft tissue abnormalities at the pelvic outlet can be corrected by performing a generous episiotomy to overcome the resistance offered by taut perineal muscles.





**Figure 3** Bony pelvic outlet obstruction due to a narrow subpubic arch.

## ASSESSING FETAL WELL-BEING DURING SECOND STAGE OF LABOR

A fetus is exposed to maximum hypoxic stress during second stage of labor, due to a combination of maternal expulsive efforts and their impact on the uteroplacental circulation, as well as repetitive and sustained compression of the umbilical cord and the fetal head.<sup>4</sup> Table 2 illustrates the detrimental effects of active potential pushing on the fetal well-being. Scientific studies have shown that there is a significant increase in fetal lactate levels with prolonged active maternal pushing.<sup>5,6</sup>

**Table 2** Detrimental effects of active maternal pushing.<sup>4</sup>

Action	Impact
Valsalva maneuver to aid expulsive efforts	Reduced venous return due to increased intrathoracic pressure resulting in reduced stroke volume and maternal cardiac output leading to a reduction <i>in utero</i> -placental circulation
Reduced maternal breathing during episodes of active maternal pushing	Reduced maternal oxygen saturation leading to reduced oxygenation of the fetus
Impaction of the fetal head deep inside the maternal birth passage	Increased fetal intracranial pressure resulting in reduced circulation through the carotid arteries, potentially reducing cerebral circulation
Lateral pressure of the fetal head on the uterine vessels	Reduced uteroplacental blood flow
Increased intrauterine pressure due to a combination of strong uterine contractions and increased intra-abdominal pressure secondary to active maternal	Repetitive and sustained compression of the umbilical cord resulting in a reduction in fetal oxygenation

## USE OF INTERMITTENT AUSCULTATION

If intermittent auscultation is used in a low-risk labor, the fetal heart rate should be regularly auscultated at least once in every 5 minutes, immediately after a uterine contraction to detect the "slow recovery of the heart rate" suggestive of the chemoreceptor-mediated "late decelerations". If any abnormality is detected during intermittent auscultation, the frequency of intermittent auscultation should be increased, and the fetal heart rate should be auscultated again during the next contraction instead of waiting for a further 5 minutes. If the observed abnormalities persist, arrangements should be made immediately for the commencement of continuous electronic fetal heart rate monitoring using the cardiotocograph (CTG), unless an immediate vaginal birth is imminent. It is essential to appreciate that accelerations of the fetal heart rate immediately after a uterine contraction, when the fetal oxygen saturation is at its lowest level, are unlikely. Therefore, if accelerations are heard during intermittent auscultation, the fetal heart rate should be auscultated throughout the next uterine contractions to detect the presence of an atypical variable deceleration, immediately followed by an exaggerated fetal reflex response to increase the baseline heart rate ("overshoots"). This is because these "overshoots" represent the attempts by the fetus to normalize his/her blood pressure in view of ongoing fetal hypotension as a result of repetitive and sustained umbilical cord compression. Presence of overshoots indicate ongoing excessive uterine activity or the presence of unrecognised oligohydramnios and/or the presence of a very thick meconium staining of amniotic fluid which predispose to sustained compression of the umbilical cord.

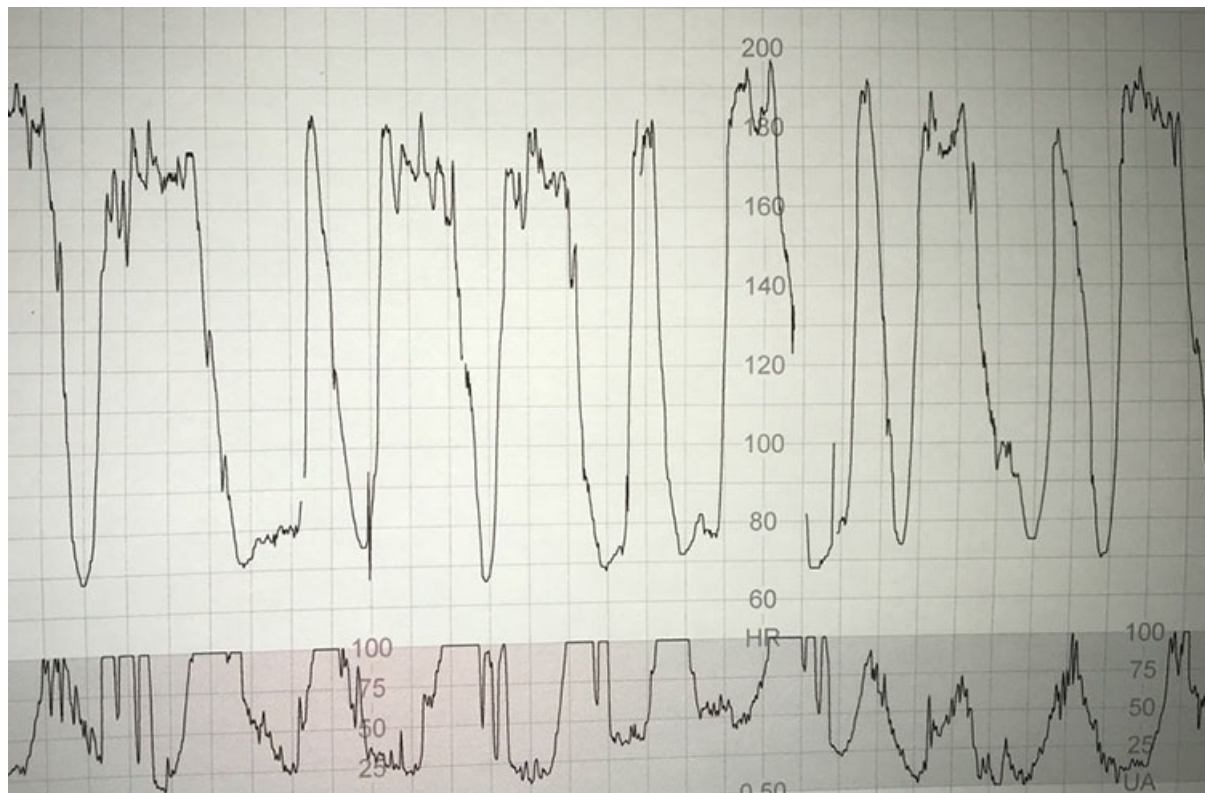
Therefore, if any abnormalities are observed on intermittent auscultation including decelerations with late recovery, the presence of repetitive accelerations or a rise in the baseline fetal heart rate for the individual fetus (compared to the previously observed baseline fetal heart rate), immediately after a uterine contraction, suggestive of a fetal catecholamine response, urgent action should be taken to avoid hypoxic ischemic encephalopathy (HIE) and/or perinatal death.

If a vaginal birth is not imminent, the woman should be transferred immediately to an obstetric unit for the commencement of CTG monitoring and/or for expediting birth based on the abnormalities observed on the CTG trace.

## USE OF CARDIOTOCOGRAPH DURING THE SECOND STAGE OF LABOR

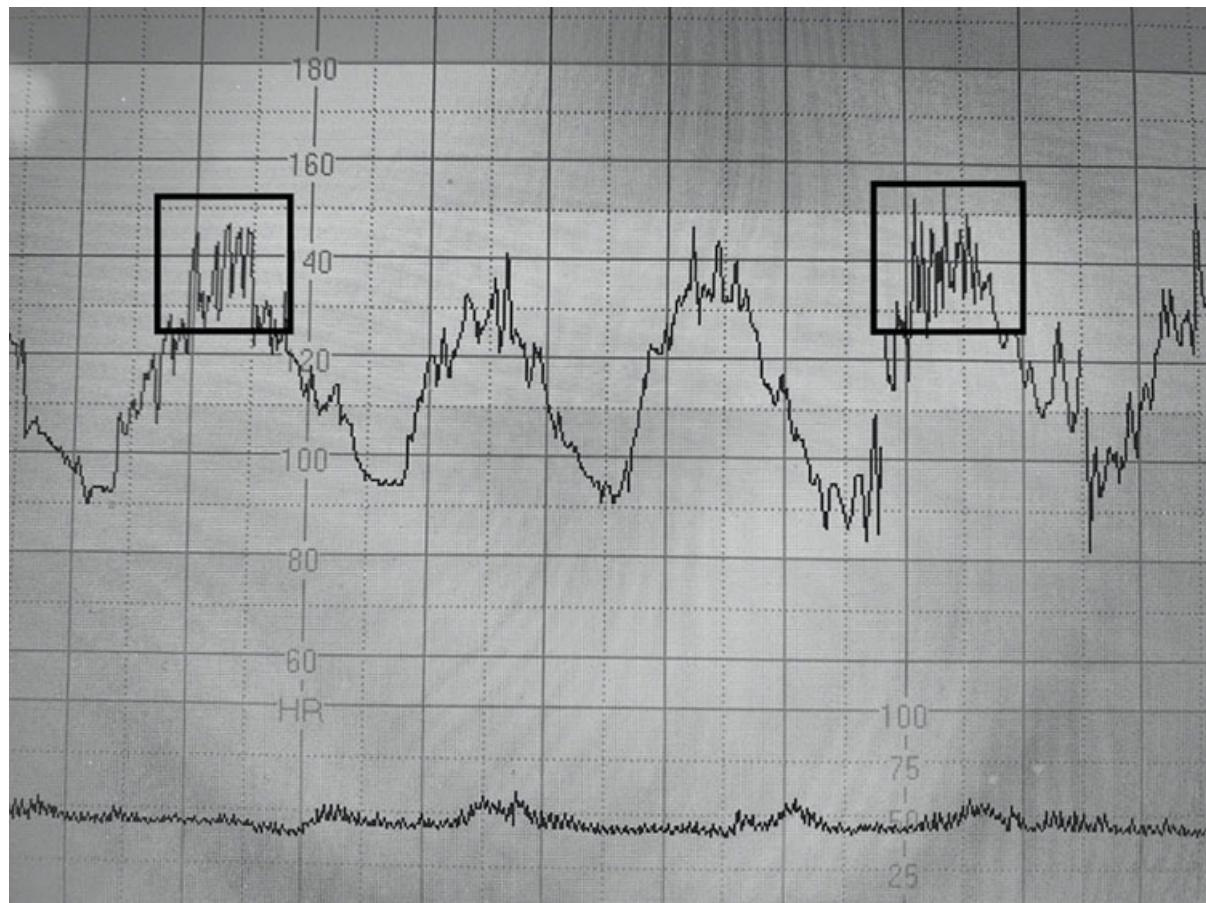
In view of the detrimental effects of active maternal pushing highlighted in Table 2, it should very be obvious to clinicians that the standard "CTG guidelines" used in the labor wards are unlikely to be useful during the second stage of labor when fetal hypoxic stress evolves very rapidly. This is because a fetus would simply have insufficient time to mount a successful compensatory response to the rapidly evolving hypoxia after the commencement of active maternal pushing.

It is important to recognise and diagnose the subacute hypoxic pattern during active second stage of labor.<sup>7</sup> The time spent at the baseline (usually <30 seconds) is insufficient to dispose of the carbon dioxide and metabolic by-products accumulated during the "deep and wide" decelerations (duration of more than 90 seconds), and to obtain sufficient oxygen from the placenta. It has been shown that due to this rapidly evolving hypoxia, the fetal pH drops at the rate of 0.01 units once in every 2–3 minutes during such a subacute hypoxic pattern (Figure 4) observed on the CTG trace.<sup>8</sup>



**Figure 4** Subacute hypoxic pattern where a fetus spends progressively less time at the baseline (<30 seconds) as compared to the time spent during the deceleration (>90 seconds).

Recently, it has been shown that such a rapidly evolving hypoxic process during active maternal pushing, a “zigzag” pattern due to autonomic instability may be observed on the CTG trace.<sup>9</sup> The zigzag pattern (Figure 5) has been reported to be associated with poor perinatal outcomes and an increased risk of admission to the neonatal unit.<sup>9</sup> Therefore, it is important to actively observe for the presence of subacute hypoxic pattern as well as the “zigzag” pattern on the CTG trace during the second stage of labor as soon as the commencement of active maternal pushing.



**Figure 5** CTG trace shows an ongoing subacute hypoxia with the “zigzag” pattern in between the “deep and wide” decelerations, during active maternal pushing.

Repetitive accelerations coinciding with uterine contractions on the CTG trace should be always considered as abnormal and unphysiological during the second stage of labor. Often, they are due to the erroneous recording of the maternal heart rate (which shows accelerations during contractions due to pain, anxiety and increased venous return) on the CTG trace. If such repetitive accelerations are observed during uterine contractions, then, the maternal pulse should be immediately checked in order to avoid poor perinatal outcomes secondary to missing ongoing abnormalities of the fetal heart rate. A fetal scalp electrode (FSE) should be considered to optimize the signal quality, if appropriate.

## RECOGNISING FETAL COMPROMISE DURING SECOND STAGE OF LABOR

The vast majority of fetuses will be able to mount a successful compensatory response to the rapidly evolving hypoxia during second stage of labor to avoid hypoxic-ischemic brain injury. However, depending on the individual fetal reserve, the intensity and rapidity of the hypoxic stress (i.e. induced or augmented labor), as well as the wider clinical picture (e.g. presence of meconium staining of amniotic fluid, maternal pyrexia or chorioamnionitis) some fetuses may be predisposed to intrapartum hypoxic injury during the second stage of labor.

In addition to the subacute hypoxic stress with a fetal catecholamine response (abrupt increase in the fetal heart rate compared to the original baseline) in between the decelerations and the “zigzag” pattern, clinicians should also be aware of the progressive reduction in the baseline heart rate. This is because the end stage of a ‘gradually evolving’ hypoxic stress is a progressive reduction in the baseline heart rate (the “step ladder pattern to death”) secondary to progressive myocardial lactic acidosis. In such cases, the catecholamine-induced increase in the baseline FHR will be followed by a reduction in baseline FHR variability suggestive of the onset of fetal metabolic acidosis.<sup>10</sup>

The presence of meconium in the amniotic fluid may be secondary to physiological maturation of the fetal gut.<sup>11</sup> However, it must be appreciated that irrespective of its classification as “significant” or “nonsignificant”, meconium has both systemic and local effects on the fetus.<sup>12</sup> Therefore, a rapidly evolving hypoxic stress indicated by ongoing subacute



hypoxic pattern or the “zigzag” pattern on the CTG may predispose to meconium aspiration syndrome. Maternal pyrexia increases maternal and fetal metabolic rates, and resultant increased oxygen consumption of tissues and organs. Therefore, if the rapidly evolving intrapartum hypoxic stress during second stage of labor is superimposed in the presence of maternal pyrexia, it can hasten hypoxic injury. Recently, it has been shown that in chorioamnionitis, loss of fetal heart rate cycling, absence of accelerations, the “zigzag” pattern, and sinusoidal pattern are common.<sup>13</sup> Therefore, these features should be actively scrutinized on the CTG trace during the second stage of labor.

## CONDUCT OF OPERATIVE VAGINAL BIRTHS

An operative vaginal birth (vacuum or forceps delivery) may become necessary for maternal (exhaustion, cardiorespiratory disorders or brain aneurysms which preclude active maternal pushing) or fetal (suspected or confirmed fetal compromise or malposition position) indications. It is very important to understand the pelvic anatomy, the mechanisms of human labor and the anatomy of the fetal skull including the important landmarks prior to embarking on an operating vaginal birth. It equally important to achieve competency and confidence prior to performing this procedure independently to avoid risks and complications as well as medicolegal pitfalls. The most important variable that ensures a successful vaginal birth with a good maternal and perinatal outcome is the knowledge, skills and competency of the operator. Chandrachan and Arulkumaran proposed a checklist “FORCEPS” to ensure that all the criteria are fulfilled prior to embarking on an operating original birth.<sup>14</sup> Table 3 illustrates a modified “FORCEPS” checklist. It is vital to remember that the main aim of obstetric practice is to ensure a healthy and undamaged mother and her baby at the end of pregnancy and childbirth. Therefore, an operative vaginal birth should not be achieved “at all cost” disregarding the potential maternal and fetal trauma. Equally, performing an emergency cesarean section during late second stage of labor is also associated with significant maternal and perinatal morbidity and mortality due to trauma whilst dislodging a deeply engaged head.<sup>15</sup> According to the recent “Early Notification Scheme Report” published by the NHS Resolution in 2019, failed instrumental deliveries and difficult delivery of the fetal head during cesarean section contributed to 11.5% and 18.4% of poor neonatal outcomes, respectively.<sup>16</sup> This illustrates the importance of ensuring a safe and effective operative vaginal birth by getting the technical aspects of operative vaginal birth right, to avoid maternal and fetal complications.

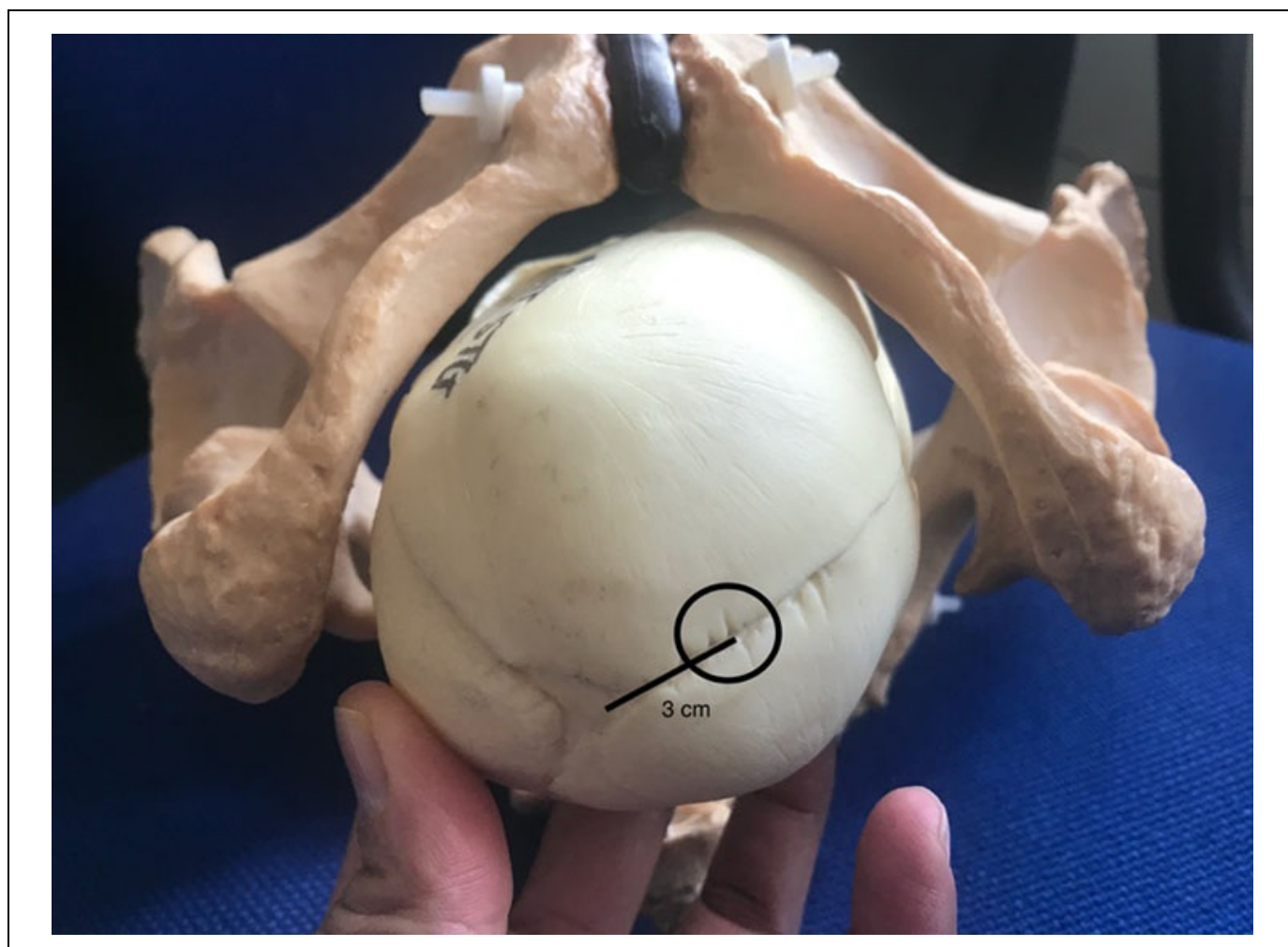**Table 3** Modified “FORCEPS” checklist prior to conducting any operative vaginal birth.<sup>14</sup>

Before any operative vaginal birth, ensure that the indication is appropriate, the woman and the multidisciplinary team are fully informed, and an experienced and competent clinician is available to undertake or to directly supervise the procedure	
<b>F</b>	Confirm that the cervix is <b>F</b> ully dilated
<b>O</b>	Exclude any mechanical <b>O</b> bstuction (<1/5 of the fetal head palpable per abdomen)
<b>R</b>	Membranes should be <b>R</b> uptured, Think “ <b>R</b> isk Management”
<b>C</b>	Obtain an informed <b>C</b> onsent, and <b>C</b> atheterise the Bladder, check <b>C</b> TG
<b>E</b>	Ensure an <b>E</b> pidural (or pudendal) analgesia, choose the right <b>E</b> nvironment (operative theater vs. delivery room), <b>E</b> xclude genital tract trauma
<b>P</b>	Determine the <b>P</b> osition, optimize the <b>P</b> ower (effective uterine contractions), <b>P</b> ause (if there is no progress with traction)
<b>S</b>	Determine the <b>S</b> tation, ensure <b>S</b> ituational Awareness & <b>S</b> cribe (clear documentation)

Excessive traction and inappropriate force should be avoided whilst conducting both vacuum and forceps births. Clinicians should exert an appropriate traction in the right direction (i.e. along the curve of Carus), while during the use of forceps, the use of the Pajot's maneuver to ensure traction at 45° along with the curve of Carus is essential. The

vacuum cup should be placed correctly at the “flexion point”, which is an arbitrary area approximately 3 cm in front of the posterior fontanelle along the sagittal suture (Figure 6). Failure to correctly place the center of the vacuum cup on the flexion point may result in serious maternal and fetal complications due to a combination of the increased diameters of the deflexed fetal head, and the resultant inappropriate and excessive traction.

Malapplication of the vacuum cup can increase the likelihood of a failed operative vaginal delivery leading to an unnecessary emergency cesarean section during second stage of labor.



**Figure 6** Note the position of the flexion point.

Rotational forceps (Kielland's) and vacuum deliveries should be performed by a skilled operator to avoid maternal and fetal trauma. In skilled hands, a rotational operative vaginal delivery during second stage of labor causes less complications as compared to an emergency cesarean section for a deeply engaged fetal head. Vacuum and forceps delivery should always be considered as complementary to each other, and they are not mutually exclusive. Considering that vacuum delivery is not possible in all cases (e.g. gross caput on the fetal head, preterm delivery or fetal bleeding disorders) and every practising obstetrician owes a duty of care to his/her patients to ensure that he/she is competent in both rotational forceps and vacuum deliveries to ensure optimum outcomes for women and babies during the second stage of labor.

---

## DURATION OF SECOND STAGE OF LABOR

---

In view of reported increase in fetal lactate levels after the onset of active maternal pushing<sup>5,6</sup> continued active maternal pushing for more than 60 minutes should be avoided, unless a spontaneous vaginal birth is imminent and the CTG trace does not show any evidence of ongoing fetal compromise. There are different schools of thought with regard to the duration of the passive second stage of labor. Most obstetricians would allow 2 hours of passive second stage of labor in women with an epidural analgesia. This is because of potential interference with the mechanism of internal rotation

secondary to epidural-induced reduced tone of the muscles of the pelvic floor. However, it must be remembered that prolonged pressure of the fetal head on the maternal pelvic floor and soft tissues may predispose to uterovaginal prolapse and urinary incontinence in later life. Therefore, care should be individualized, and a vaginal examination is recommended after 1 hour of passive second stage even in women with an epidural analgesia. If the fetal vertex is at or below the ischial spines, and is in an occipito-anterior position, then active pushing should be commenced after 1 hour. In cases of malposition or if the fetal vertex is above the level of the ischial spines, then, it is reasonable to avoid more time to facilitate descend and internal rotation, prior to commencing active maternal pushing.

---

## REDUCING RISKS DURING SECOND STAGE OF LABOR

---

Due to the rapidly evolving hypoxia and the need for clinicians to make quick decisions in a highly charged and rapidly changing environment, it should be of no surprise that the second stage of labor is associated with significant malpractice claims.<sup>17</sup> A 5-year study in a tertiary institution has reported that the implementation of an intense hands-on training on operative vaginal births can lead to a significant reduction in the incidence of failed operative vaginal births.<sup>18</sup> Therefore, not only the constant and continuous training of obstetricians of all grades on the conduct of operative vaginal births is essential, but also that monitoring the outcomes by clinical governance tools such as the “maternity dashboard”<sup>19</sup> are equally important to help reduce risk incidents and litigation during second stage of labor. Specific and targeted training on the use of CTG during the second stage of labor should be instituted for all midwives and obstetricians caring for women during labor. Such training should include the recognition of the features of erroneous maternal heart rate recording,<sup>20</sup> as well as the CTG features expected during operative vaginal births to optimize perinatal outcomes.<sup>21</sup>

---

## PRACTICE RECOMMENDATIONS

---

- **The second stage of labor is the most dangerous time for both the mother and her fetus due to the rapid evolution of fetal hypoxic stress, and the effects of the advancing bony fetal head on the soft tissues of the maternal birth passage.**
- **The effectiveness of the ‘Power’, the roominess of the “Passage”, and the well-being and the size, position and attitude of the “Passenger” should be considered, whilst making management decisions.**
- **Standard CTG guidelines are unlikely to be useful in the presence of rapidly evolving fetal hypoxic stress. Recognition of the subacute hypoxia and the “zigzag” pattern is essential.**
- **Accelerations during intermittent auscultation, and accelerations coinciding with uterine contractions are both unphysiological during second stage of labor**
- **The “FORCEPS” checklist is recommended to avoid errors during operative vaginal births that may result in maternal and perinatal complications**
- **Risk management should include an intense “hands on training” on operative vaginal births, and continuous monitoring of the outcomes by using the “maternity dashboard”.**

### CONFLICTS OF INTEREST

*The authors of this chapter declare that they have no interests that conflict with the contents of the chapter.*

## REFERENCES

- 1 Uvnäs-Moberg K, Ekström-Bergström A, Berg M. *et al.* Maternal plasma levels of oxytocin during physiological childbirth – a systematic review with implications for uterine contractions and central actions of oxytocin. *BMC Pregnancy Childbirth* 2019;19:285. <https://doi.org/10.1186/s12884-019-2365-9>
- 2 Wathes DC, Borwick SC, Timmons PM, *et al.* Oxytocin receptor expression in human term and preterm gestational tissues prior to and following the onset of labour. *J Endocrinol* 1999;161(1):143–51.
- 3 Bukhari H, Chandraharan E. Physiopharmacology of Labour. In: Arulkumaran S, Arjun G, Penna LK. (eds.) *The Management of Labour*, 3rd edn. University Press, 2011.
- 4 McDonnell S, Chandraharan E. Fetal heart rate interpretation in the second stage of labour: pearls and pitfalls *British Journal of Medicine and Medical Research* 2015;7:957–970.
- 5 Nordström L, Malcus P, Chua S, Shimojo N, Arulkumaran S. Lactate and acid-base balance at delivery in relation to cardiotocography and T/QRS ratios in the second stage of labour. *Eur J Obstet Gynecol Reprod Biol* 1998;76(2):157–60.
- 6 Nordström L, Achanna S, Naka K, Arulkumaran S. Fetal and maternal lactate increase during active second stage of labour *BJOG* 2001;108(3):263–8.
- 7 Chandraharan E, Arulkumaran S. Prevention of birth asphyxia: responding appropriately to cardiotocograph (CTG) traces. *Best Pract Res Clin Obstet Gynaecol* 2007;21(4):609–24
- 8 Pinas A, Chandraharan E. Continuous cardiotocography during labour: Analysis, classification and management. *Best Pract Res Clin Obstet Gynaecol* 2016;30:33–47.
- 9 Gracia-Perez-Bonfils A, Vigneswaran K, Cuadras D, *et al.* Does the saltatory pattern on cardiotocograph (CTG) trace really exist? The ZigZag pattern as an alternative definition and its correlation with perinatal outcomes. *J Matern Fetal Neonatal Med* 2019;1–9.
- 10 Jia YJ, Chen X, Cui HY, *et al.* Physiological CTG interpretation: the significance of baseline fetal heart rate changes after the onset of decelerations and associated perinatal outcomes [published online ahead of print, 2019 Sep 18]. *J Matern Fetal Neonatal Med* 2019;1. doi: 10.1080/14767058.2019.1666819. Format:
- 11 Mitchell S, Chandraharan E. *Meconium-stained amniotic fluid, Obstetrics, Gynaecology and Reproductive Medicine* 2018. <https://doi.org/10.1016/j.ogrm.2018.02.004>
- 12 Bolten M, Chandraharan E. The Significance of 'Non-Significant' Meconium Stained Amniotic Fluid (MSAF): Colour versus Contents. *Journal of Advances in Medicine and Medical Research* 2019;30(5):1–7.
- 13 Galli L, Whelehan V, Archer A, *et al.* Perinatal outcomes in fetuses with cardiotocography (CTG) changes suggestive for chorioamnionitis. *European Journal of Obstetrics and Gynecology and Reproductive Biology* 2019;234:e4
- 14 Chandraharan E, Arulkumaran S. Operative delivery, shoulder dystocia and episiotomy. In: Arulkumaran S, Penna LK, Bhaskar Rao K. (eds.) *The Management of Labour*, 2nd edn. Orient Longman, 2005.
- 15 Manning JB, Tolcher MC, Chandraharan E, *et al.* Delivery of an Impacted Fetal Head During Cesarean: A Literature Review and Proposed Management Algorithm. *Obstet Gynecol Surv* 2015;70(11):719–24. <https://resolution.nhs.uk/wp-content/uploads/2019/09/NHS-Resolution-Early-Notification-report.pdf>
- 16 NHS Resolution. The Early Notification scheme progress report: collaboration and improved experience for families. September 2019 <https://resolution.nhs.uk/wp-content/uploads/2019/09/NHS-Resolution-Early-Notification-report.pdf>
- 17 Chandraharan E, Arulkumaran S. Medico-legal Problems in Obstetrics. *Obstetrics, Gynaecology and Reproductive Medicine* 2006;16(4):206–210.
- 18 McDonnell S, Chandraharan E. Determinants and Outcomes of Emergency Caesarean Section following Failed Instrumental Delivery: 5-Year Observational Review at a Tertiary Referral Centre in London. *J Pregnancy* 2015;2015:627810.
- 19 Chandraharan E, Arulkumaran S. The role of clinical dashboards in improving patient care: experience with the 'Maternity Dashboard'. *Ceylon Med J* 2016;61(2):83–5. doi: 10.4038/cmj.v61i2.8291.
- 20 Nurani R, Chandraharan E, Lowe V, *et al.* Misidentification of maternal heart rate as fetal on cardiotocography during the second stage of labor: the role of the fetal electrocardiograph. *Acta Obstet Gynecol Scand* 2012;91(12):1428–32.
- 21 Xie W, Archer A, Li C, *et al.* Fetal heart rate changes observed on the CTG trace during instrumental vaginal delivery. *J Matern Fetal Neonatal Med* 2019;32(1):117–124.